

Patrick Tonnard · Alexis Verpaele

## 300 MACS-lift short scar rhytidectomies: analysis of results and complications

Received: 16 September 2004 / Accepted: 8 December 2004 / Published online: 30 April 2005  
© Springer-Verlag 2005

**Abstract** Between November 1999 and April 2004, 300 MACS-lifts (Minimal Access Cranial Suspension–lifts) were performed. Starting from the idea of suspension of sagged soft tissues with permanent purse-string sutures, a new comprehensive approach to facial rejuvenation was developed, in which the vertical vector appeared to be essential. The neck is corrected by extended submental liposuction and strong vertical traction on the lateral part of the platysma by means of a first vertical purse-string suture. The volume of the jowls and the cheeks is repositioned in a cranial direction with a second, slightly-oblique purse-string suture. The descent of the midface is corrected by suspending the malar fat pad in a nearly vertical direction. The skin excess generated by these actions is redraped in a pure vertical direction and excised at the temporal hairline and the paracanthal region. As no horizontal pull on the skin is exerted, a retro-auricular incision becomes obsolete. The result is a pure antigravitational lifting procedure, which produces a natural facial rejuvenation through a short scar.

### Methods

The MACS-lift is a facial rejuvenation procedure for correction of the aging neck and lower and middle thirds of the face. It is usually performed under local anaesthesia with minimal sedation. The authors have extensively described the basic technique elsewhere [14, 15].

The core principle of the technique is a pure antigravitational facial rejuvenation by acting on the deep facial soft tissues and the skin in the same vertical direction.

A limited skin undermining is performed through a preauricular and temporal prehairline incision. The temporal hairline incision is done in a zigzag pattern (Fig. 1), with inclination of the knife perpendicularly to the orientation of the hair shafts (Fig. 2). Strong non-resorbable purse-string sutures (Prolene 2-0 or Mersilene 2-0) are anchored to the deep temporal fascia above the zygomatic arch.

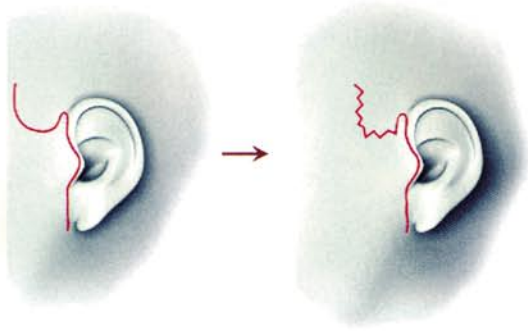
A *simple* MACS-lift, with effect on the neck and the lower third of the face and an *extended* MACS-lift, with an additional effect on the middle third of the face, were developed.

In the *simple* MACS-lift (Fig. 3), two purse-string sutures are used for correction of the neck, the jowls and the marionette grooves. They are both anchored to the deep temporal fascia above the zygomatic arch 1 cm in front of the auricular helix. The first suture runs as a narrow vertical U-shaped purse string to the region of the mandibular angle. Tying this suture under maximal tension produces a strong vertical pull on the lateral part of the platysma muscle, correcting the neck region, which has been liposuctioned previously. The second purse-string suture starts from the same anchoring point above the zygomatic arch, and runs obliquely in the direction of the jowls as a wider O-shaped loop. This suture corrects the jowls, the marionette grooves and the downward slanting of the corners of the mouth.

When performing an *extended* MACS-lift (Fig. 4), an additional undermining of the skin over the malar region is performed. A point dropped 2 cm below the lateral canthus has been marked with the patient in the standing position. It will be included in the skin undermining and is the inferior limit of the third purse-string suture. This suture also originates from the deep temporal fascia, but in its anterior part, lateral to the lateral orbital rim. It provides a strong correction of the nasolabial fold, an enhancement of the malar region, a lifting of the midface and a shortening of the vertical height of the lower eyelid [10].

In simple as well as in extended MACS-lifting, the skin is redraped in a pure vertical direction and the

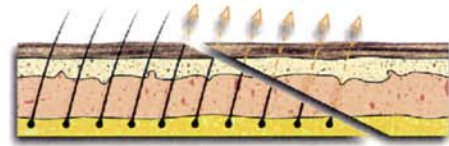
P. Tonnard (✉) · A. Verpaele  
Coupure Centrum voor Plastische Chirurgie,  
Universitair Ziekenhuis Gent, Gent, Belgium  
E-mail: patrick@coupurecentrum.be



**Fig. 1** Change of the original linear temporal incision into a zigzag one. The zigzag incision will unfold and stretch into a linear scar when it is coapted to the linear resection border or the cheek flap after resection of the skin flap. The zigzag pattern will compensate for the incongruence in length between incision and excision border, and the risk of dog-ears in this region will be reduced

excess skin is excised to adapt to the temporal incision.

When using the third suture in extended MACS-lift, a skin excess appears at the lateral lower eyelid and



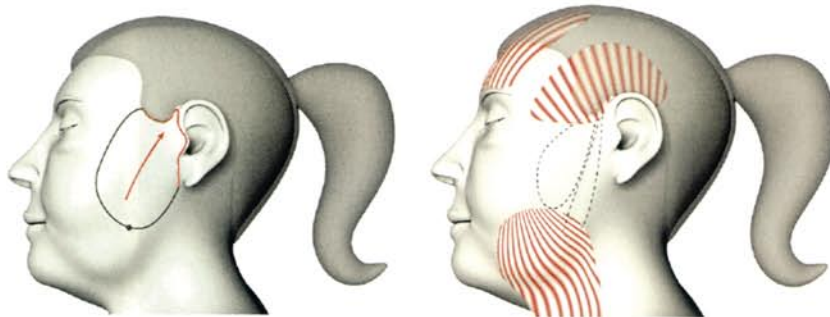
**Fig. 2** According to Camirand, the incision in the temporal area is made perpendicularly to the hair shafts. This will allow hair regrowth through the scar and through the skin in front of the scar, thus hiding the scar within the hair-bearing skin

paracanthal area. It is excised at the end of the procedure through a lower blepharoplasty incision (pinch blepharoplasty).

A silicone tube is placed for drainage before closure and the patient is discharged 2 h later.

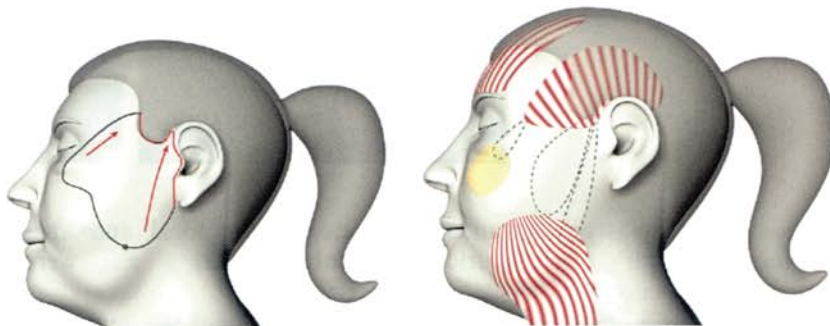
**Results**

Between November 1999 and April 2004, 300 MACS-lifts were performed. Twenty-four cases (8%) were done in men, and 36 cases (12%) were secondary rhytidectomies. The mean age at surgery was 56 years, with a minimum of 39 years and a maximum of 85 years. In 15 cases (5%), additional neck work was done through an



**Fig. 3** In a simple MACS-lift, a preauricular and temporal hairline incision is performed. Cheek skin is undermined as indicated on the left image. A first narrow U-shaped purse-string suture is anchored into the deep temporal fascia in front of the helical rim, and woven

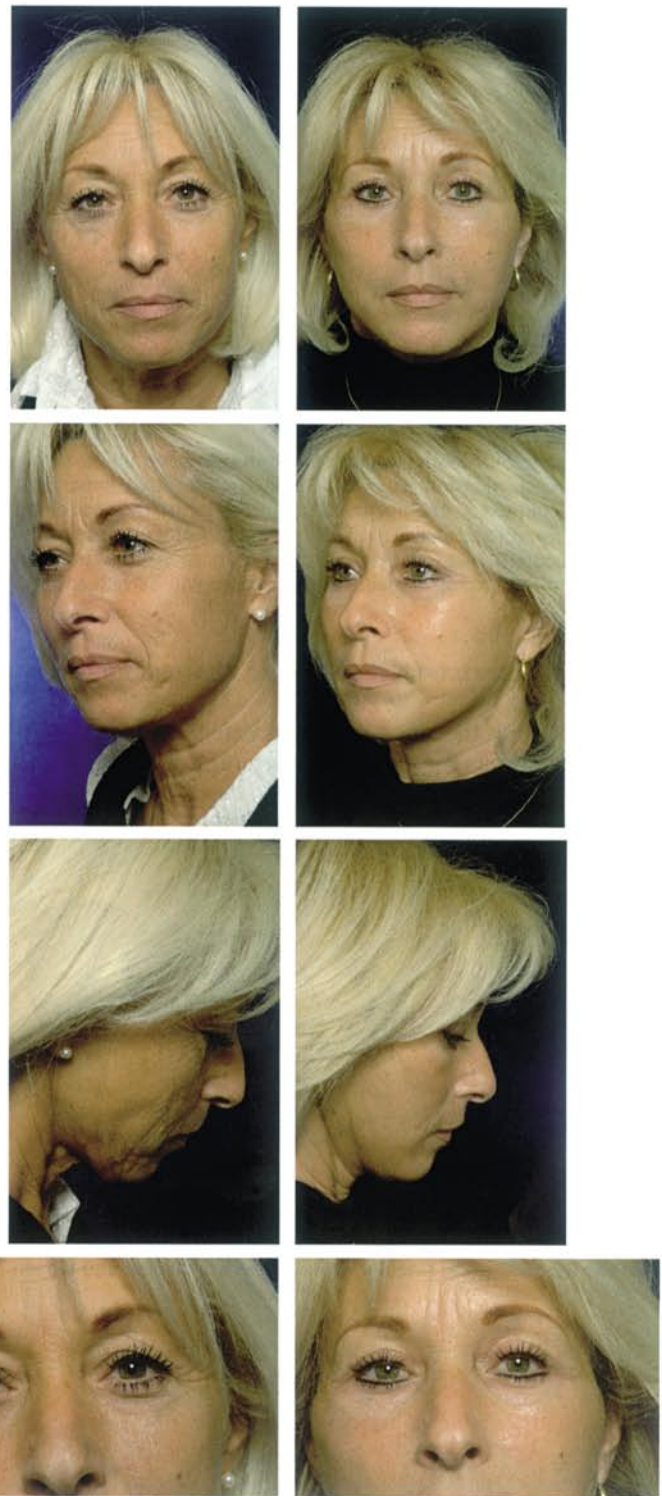into the SMAS tissue, which is not undermined. The second purse-string suture starts at the same anchor point and follows the borders of the undermining in a more open O-shaped loop



**Fig. 4** In the extended MACS-lift, the incision is extended 1–2 cm along the anterior temporal hairline. A supplementary area over the malar fat pad is undermined, as seen on the left image. The third purse-string suture has a narrow U shape, with its anchor

point located in the most anterior part of the deep temporal fascia, just lateral to the lateral orbital rim. This suture suspends the malar fat pad, correcting the nasolabial groove and the midface area

**Fig. 5** This 49-year-old lady underwent an extended MACS-lift with submental liposculpture, upper blepharoplasty and lower pinch blepharoplasty. On the *right*, the result is seen 8 months postoperatively. One sees a tightening of the whole neck area, correction of the jowling, softening of the nasolabial folds and a general lifting of the midface. The eyes look more youthful as a result of a better transition of the eyelid skin into the cheek skin and correction of the hooding under the lateral part of the eyebrow



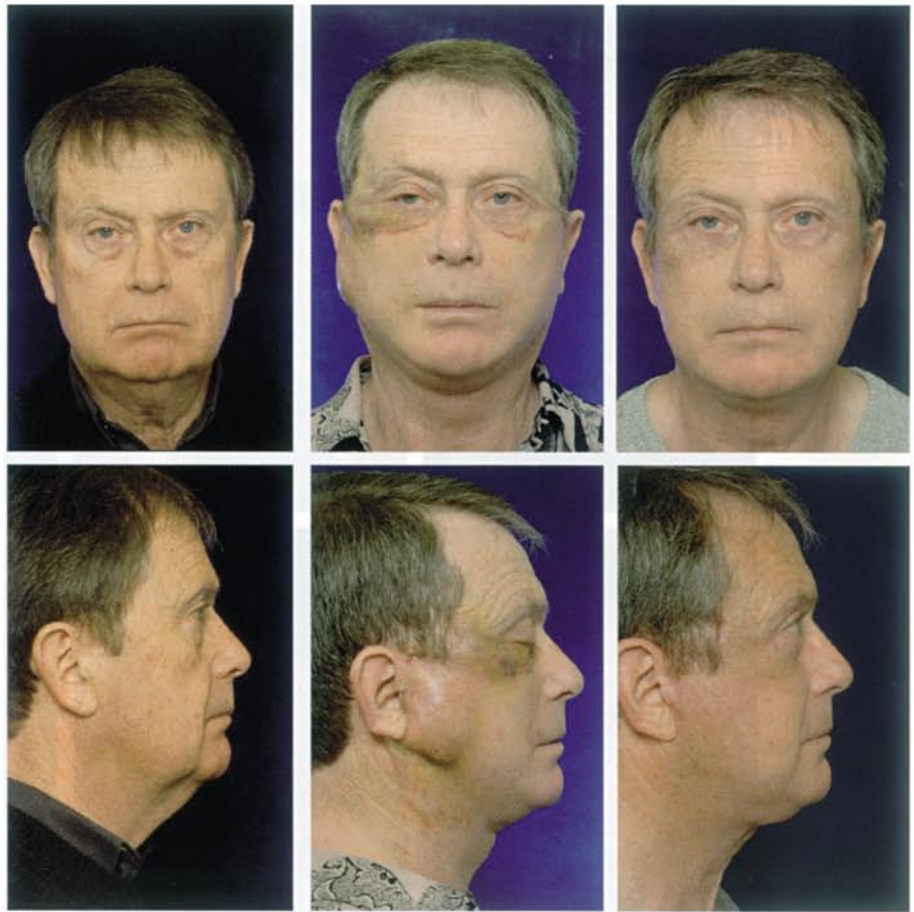anterior cervicoplasty (resection of platysmal bands) and/or posterior cervicoplasty (redraping of retroauricular skin via occipital pre-hairline incision).

Thirty-six percent of the cases (108 cases) were done under general anaesthesia in the hospital, according to the patient's preference or because of medical conditions (cardiac pathology, hypertension, epilepsy, etc.). The remaining patients (64%) were

operated under local anaesthesia with intramuscular midazolam sedation, and were discharged 2 h after surgery.

General patient satisfaction was very high, and 78% of the patients were able to restart their social and professional activities 2 weeks after the surgery. Following a retrospective survey which we organized on 120 consecutive patients, the answers of 99 respondents were

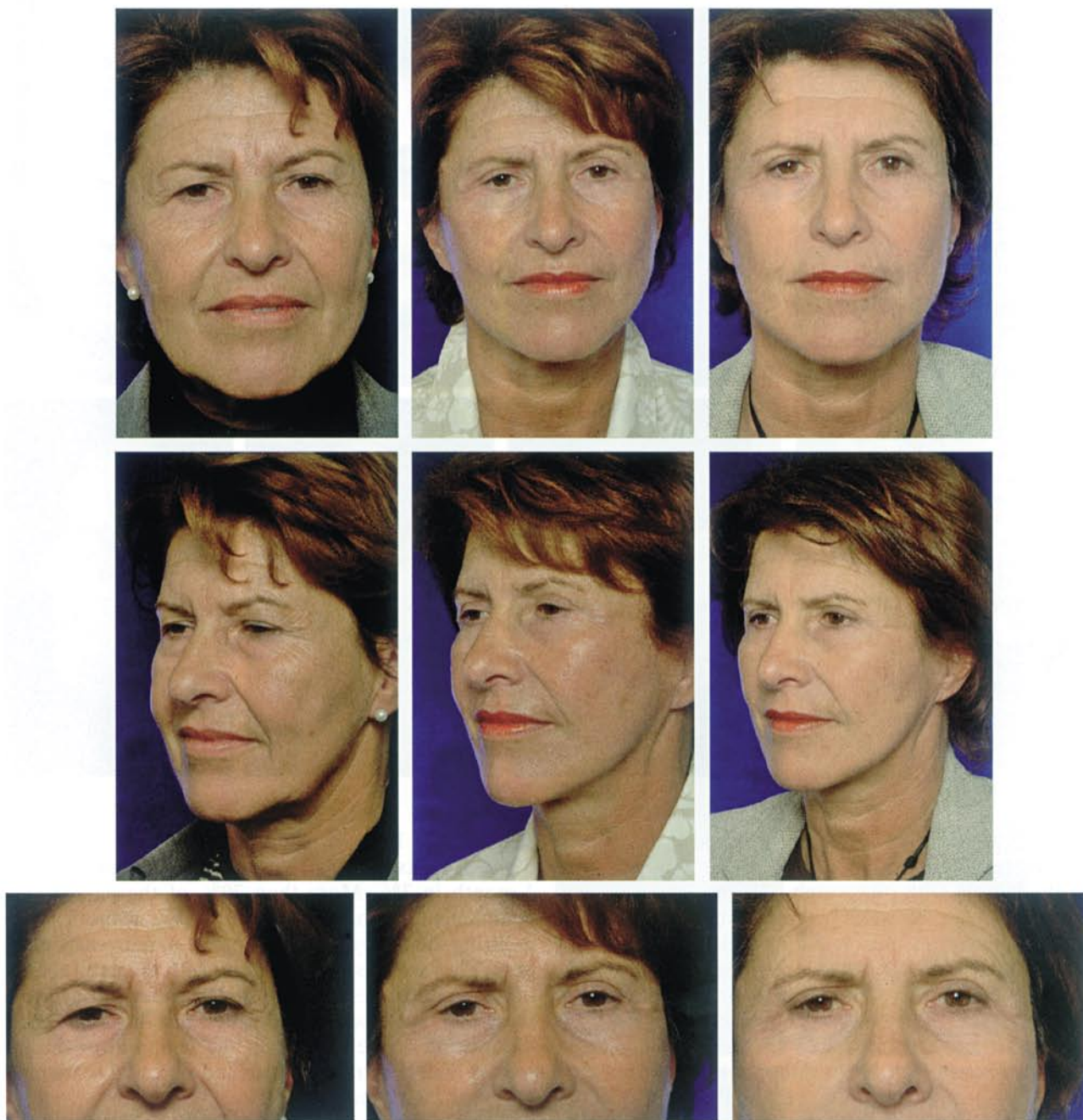**Fig. 6** This 60-year-old patient underwent an extended MACS-lift, a submental liposculpture, a transconjunctival fat removal and a pinch lower blepharoplasty under general anaesthesia according to his own preference. He developed a haematoma 1 week after surgery (*middle images*), which was drained under local anaesthesia on an outpatient basis. The final result was not influenced by this minor but annoying event. The 1-year postoperative result (images on the *right*) reveals a stable correction of the patient's aging facial features. The cervicomenal angle has been reconstructed without opening the neck. Correction of the jowling with a better definition of the jaw line is obvious. The downward slanting of the corners of the mouth was corrected and a general triangularization of the square face is obvious, as seen in the frontal view. In the profile view, note the inconspicuous preauricular and temporal hairline scar and an unaltered position of the sideburns



evaluated. All patients had been operated more than a year before. Seventy-nine percent were happy or extremely happy with the result. Twenty percent had slightly higher expectations from the surgery, but none of these patients was absolutely dissatisfied with the result. Ninety-two percent of the respondents would recommend this intervention to friends or family. Among the patients that were operated under local anaesthesia, 34% experienced the surgery as absolutely not distressing or unpleasant. For 58% of the patients, the surgery was mildly uncomfortable, but very well tolerated. Eight percent experienced the surgery as unpleasant. Ninety-one percent would repeat their MACS-lift if considered necessary. Sixteen percent of the patients who had their surgery under local anaesthesia would choose general anaesthesia for a secondary face-lift. Nine percent would not consider a reoperation for different reasons. The final decision to choose MACS-lift surgery was taken because of the possibility of performing the surgery under local anaesthesia in 24% of cases; the shorter scar, the shorter operating time, the quick recovery and the absence of hospital stay was indicated in 64% of the patients. Twenty-three percent of the patients had been considering a facial rejuvenation procedure for less than 1 month, 33% between 1 and 6 months, 27% between 6 months and 2 years and 17% for more than 2 years. Social and professional inactivity after MACS-lift

surgery was 1 day in 1%, 1 week in 18%, 2 weeks in 59%, 3 weeks in 14%, 1 month in 5% and more than 1 month in 3%. More than 70% of the patients were complimented on their good looks, without people realizing that they had undergone a rejuvenation surgery. They were especially happy with the natural aspect of the surgical result (Fig. 5), the short inconspicuous scars and the absence of dreaded face-lift stigmata [5], like raising of the hairline in the temporal or occipital region, visible retro auricular and occipital scars or the so-called "wind-tunnel look".

The incidence of major complications like skin slough, permanent facial branch paralysis or ectropion was zero. The incidence of minor complications was also low. Hematoma that required surgical drainage under local anaesthesia appeared in 2% (six cases) (Fig. 6). Three cases (1%) of infection in the horizontal limb of the scar were treated with oral antibiotics. A suppurating subcutaneous Vicryl suture seemed to be the cause. The knots of the Prolene suture were palpable in ten cases and were irritating in six cases (2%), for which we proposed the removal of the suture under local anaesthesia at 6 months postop. No deterioration of the result was seen after suture removal. Especially after removal of the third suture (three cases), with a palpable knot at the thinned lateral orbital region, there was no occurrence of ectropion or scleral show on a long-term basis (Fig. 7).



**Fig. 7** This 60-year-old woman presented with marked jowling and loss of definition of the jaw line, and an obtuse cervicomental angle with obvious platysmal bands. She also complained of a tired look around the eyes. Facial rejuvenation was proposed under local anaesthesia with intramuscular midazolam sedation. The surgical plan consisted of performance of an extended MACS-lift with submental liposuction, upper blepharoplasty and lower pinch blepharoplasty. The result is seen 8 (*middle images*) and 18 months (*right images*) after surgery. Note the good correction of the facial volumes in an upward direction. The upper neck is corrected

without opening the neck. Jowling, marionette grooves and the nasolabial folds are well corrected, and the vertical height of the lower eyelid is diminished, resulting in a better transition from eyelid skin to cheek skin. In the *frontal view* of the middle images, note the existence of two palpable and visible subcutaneous knots in the lateral orbital region from the Prolene purse-string suture. These were removed via a stab incision 8 months postoperatively. The final result as seen at 18 months postop (*right images*) was not altered by this intervention

## Discussion

Minimally-invasive surgical techniques are welcomed in many surgical disciplines as well as in aesthetic surgery

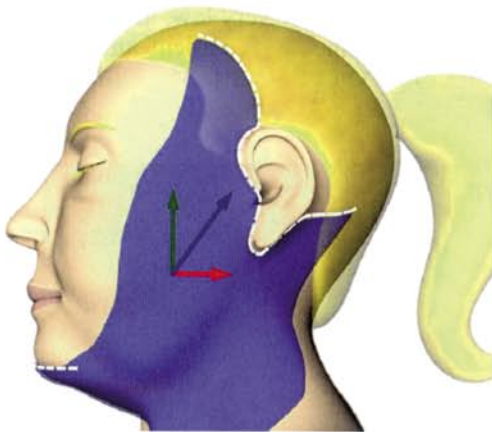
techniques, as long as the quality of the result remains good and the complication rate stays low [1, 11, 12].

Most classical face-lifts act on the subcutaneous or SMAS level with an oblique cranio-posterior vector. The

skin redraping is usually done in a more posterior vector, taking care not to raise the temporal hairline too much [7, 13].

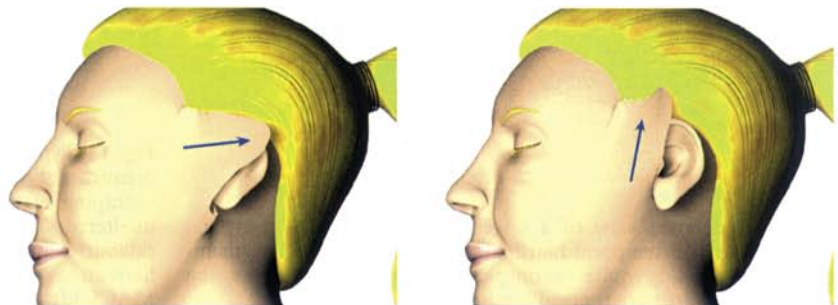
Any oblique vector can be divided into a horizontal and a vertical component (Fig. 8). It is our opinion that the horizontal vector only produces flattening on the face, whereas the vertical vector is the rejuvenating one. A pure vertical vector on the deep tissues and the skin produces the same rejuvenating effect without flattening the face. Moreover this avoids the need for a retroauricular incision (Fig. 9). This vertical vector is also important in correcting the neck. Strong vertical pull in the lateral region of the platysma muscle mostly corrects the more medially located platysmal band, as can be simulated in front of the mirror by pulling the region of the mandibular angle upwards. This is exactly the action of the first purse-string suture.

Suturing the platysmal bands together at the midline may produce a hammock effect [4], but seems to us unphysiological, as the medial platysmal edges of the muscle were never joined at the midline at a younger age. Moreover, suturing the platysmal edges medially produces a downward pull on the cheek volumes that acts against the desired lifting effect in the lower face.



**Fig. 8** Traditional face-lift designs all have an oblique vector of traction on the SMAS and/or the skin (blue arrow). This vector can be separated into a horizontal (red arrow) and a vertical component (green arrow). In recent years, more emphasis has been placed on reorienting this vector in a vertical direction. The hypothesis of short-scar vertical-vector face lifting is that horizontal traction on facial deep tissues and skin is not rejuvenating

**Fig. 9** When lateral skin redraping is performed, as in classical face-lifts, a dog-ear appears at the earlobe, which necessitates redraping by retroauricular flap dissection (left image). Vertical skin redraping, on the contrary, will not produce any dog-ear under the earlobe and will avoid the necessity for retroauricular dissection (right image)

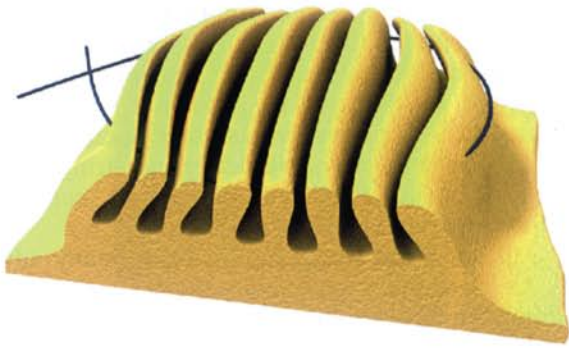


Platysmorrhaphy is not exempt of complications [6, 9]: increased incidence of haematoma, risk of contour deformities by over-resection of subplatysmal fat or loosening of the raphy. The good and stable results obtained with extensive supraplatysmal suction lipectomy, combined with strong vertical purse-string suspension of the platysma, made us almost completely abandon classical platysmorrhaphy.

The use of purse-string sutures offers many advantages. As the suture is weaved into the tissue with several firm bites, the forces of the pull are distributed along the circumference of the purse-string. This stands in contrast to a cable suture between two anchor points, where everything relies on the firmness of the grabbed tissues. The pursestring sutures in the MACS-lift technique work like a facial sculpturing technique by multiple microimbrications (Fig. 10). The skin redraping and resection in the same vertical direction act like a lock on the subcutaneous sculpturing result.

The trend in facial rejuvenation during the last decade has clearly been towards volume displacement [8] or replacement [3] instead of producing tension in the face. For relocation of facial tissues, several dissection planes can be chosen. The ideal intervention should deliver maximal efficiency at a minimal risk. Subcutaneous dissection and direct action on the subcutaneous tissues with suture techniques like in the MACS-lift technique is a quick, simple and safe technique, which produces predictable and stable results, with a very swift recovery.

Temporal pre-hairline incisions are unpopular because of fear concerning the visibility of the scar. The quality of the scar can be improved greatly by little tricks. The horizontal limb of the originally-described inverted L-shaped incision was converted into a zigzag-shaped one for two reasons. First, an irregular scar at the border of the hairline is less visible than a linear one. Second, there exists an incongruence in length between the temporal hairline incision and the cranial border of the cheek flap after resection of the skin excess. The zigzag pattern increases the length of the skin edge at the hairline, thereby reducing the formation of dog-ears in this region (Fig. 1). In short-scar face lifting, reduction of dog-ear formation is crucial. Moreover, as the inclination of the incision is oriented perpendicularly to the hair shafts, hair growth will occur through the scar (Fig. 2). This will make the final scar even more inconspicuous as it will be located within the hair-bearing area [2].

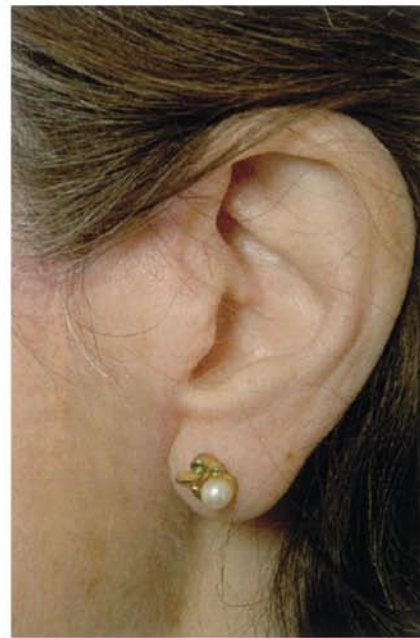

**Fig. 10** The purse-string suture technique, as applied in the MACS-lift, is a facial sculpturing technique that acts by the mechanism of multiple microimbrications of the subcutaneous tissues

The quality of the preauricular scar is of utmost importance to avoid face-lift stigmata. As skin redraping and resection, in the MACS-lift, is only performed in a vertical direction, an absolutely tension-free preauricular closure is possible, producing excellent quality scars (Figs. 11, 12, 13, 14).

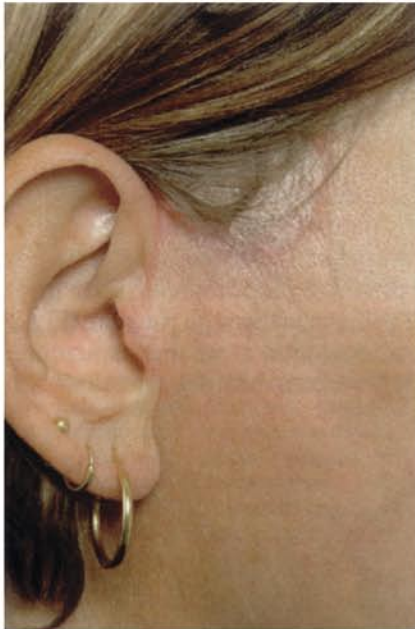
### Conclusion

The MACS-lift is a short-scar rhytidectomy technique that produces very pleasing and natural facial rejuvenation results through pure vertical shifting of facial deep tissues and skin. The technique can be performed under local anaesthesia in an office-based practice. Morbidity

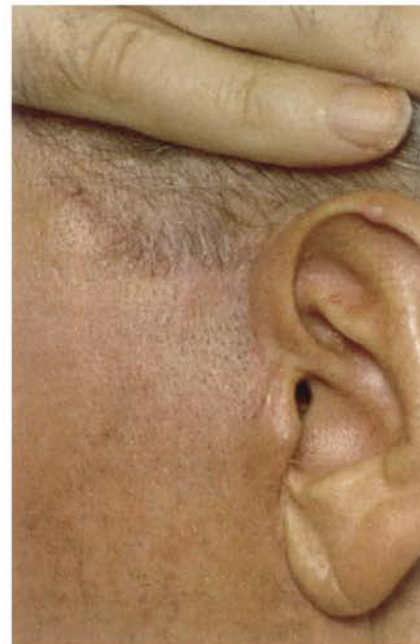

**Fig. 12** One-year postop detailed view of the preauricular scar. Note the unaltered shape and position of the auricle, avoiding any face-lift stigmata

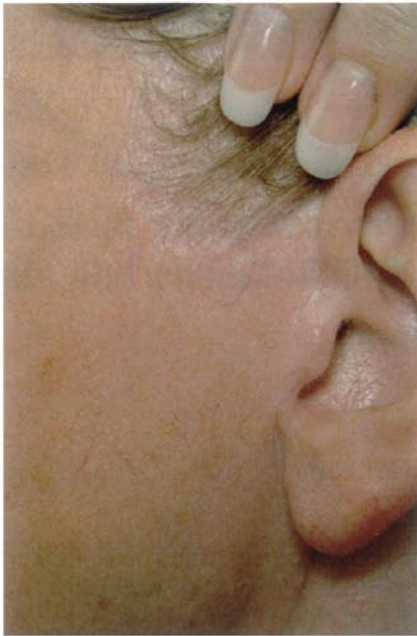and complication rate are very low, and the results seem to be stable over time. Both patient and surgeon satisfaction are high. On this basis, MACS-lifting can be a valuable tool in a modern face-lift practice.



**Fig. 11** A detailed view of a 6-week postop result of a typical preauricular and temporal hairline scar. The scar is still erythematous but already quite inconspicuous because it follows the borders of distinct anatomical landmarks



**Fig. 13** Typical long-term result in a male with inconspicuous preauricular and temporal hairline scar. Thanks to the pure vertical redraping of the cheek skin flap, the position of the sideburn is unaltered. This also results in a hair-free tragus, a natural male sideburn, and a normal position of the beard growth. A short haircut, as often worn by men, is perfectly possible with the MACS-lift technique



**Fig. 14** Typical long-term result of a preauricular and temporal hairline scar after extended MACS-lifting. Note the unaltered natural position of the auricle and the inconspicuous irregular temporal prehairline scar, where hair regrowth through the scar conceals its visibility

---

## References

1. Baker DC (2001) Minimal incision rhytidectomy (short-scar face lift) with lateral SMASectomy: evolution and application. *Aesthetic Surg J* 21:14
2. Camirand A, Doucet J (1997) A comparison between parallel hairline incisions and perpendicular incisions when performing a face-lift. *Plast Reconstr Surg* 99:10
3. Coleman SR (1997) Facial recontouring with lipostructure. *Clin Plast Surg* 24:347
4. Feldman JJ (1990) Corset platysmaplasty. *Plast Reconstr Surg* 85:333
5. Franco T (1985) Face-lift stigmata. *Ann Plast Surg* 15:379
6. Grover R, Jones BM, Waterhouse N (2001) The prevention of hematoma following rhytidectomy: a review of 1078 consecutive facelifts. *Br J Plast Surg* 54(6):481–486
7. Hamra ST (1992) Composite rhytidectomy. *Plast Reconstr Surg* 90:1
8. Little JW (2000) Three-dimensional rejuvenation of the mid-face: volumetric resculpture by malar imbrication. *Plast Reconstr Surg* 105:267
9. Matarasso A, Elkwood A, Rankin M, Elkowitz M (2000) National plastic surgery survey: face lift techniques and complications. *Plast Reconstr Surg* 106:1185
10. Owsley JQ, Fiala TJ (1997) Update: lifting the malar fat pad for correction of prominent nasolabial folds. *Plast Reconstr Surg* 100:715
11. Pitman GH (2001) Commentary on minimal incision rhytidectomy (short scar face lift) with lateral SMASectomy: evolution and application by Baker DC. *Aesthetic Surg J* 21:14
12. Ramirez OM (1996) Subperiosteal minimally invasive laser endoscopic rhytidectomy: the SMILE facelift. *Aesth Plast Surg* 20:463
13. Stuzin JM, Baker TJ, Gordon HL (1995) Extended SMAS dissections. An approach to midface rejuvenation. *Clin Plast Surg* 22:295
14. Tonnard P, Verpaele A (2004) *The MACS-lift Short Scar Rhytidectomy*. Quality Medical Publishing, St Louis
15. Tonnard P, Verpaele A et al (2002) Minimal access cranial suspension lift: a modified S-lift. *Plast Reconstr Surg* 109:2074